


SHOCK WAVE  
THERAPY IN  
PRACTICE

# ENTHESIOPATHIES II

RADIAL SHOCK WAVE TREATMENT  
OF TENDINOPATHIES

ULRICH DREISILKER

LEVEL 10 



4<sup>th</sup> edition September 2015  
Print run: 2000  
All rights reserved.  
Leveho Buchverlag Daniela Bamberg,  
Lise-Matzen-Str. 6, 74074 Heilbronn, Germany, www.level-books.de

Author: Dr. Ulrich Drexler  
Photos: Christian Sadofsky

All parts of this publication are copyright-protected. Any use outside the limits of the Copyright Law is not permitted without the publisher's permission and is liable to prosecution. This particularly applies to reproduction, translation, microfilming and storage and processing in electronic systems.

The use of generic names, trade names, product designations etc. does not imply, even in the absence of a specific statement, that such names are exempt from the relevant protective laws and regulations and therefore free for general use.

Design: BAMBERG kommunikation GmbH  
Printing and binding: WALTER Medien GmbH  
Raffelsteinstraße 49-55, 74136 Brackenheim-Hausen  
Printed in Germany

ISBN 978-3-94506-04-4

## CONTENTS

### General section

Foreword	Martin Ringeman	12
Introduction	Ulrich Drexler	14
Insertion tendinopathies and trigger points	Ulrich Drexler	22
Literature research on the effectiveness of RSWT	Ulrich Drexler	26
History, clinical diagnosis, therapeutic measures	Ulrich Drexler	32
Diagnostic sonography	Ulrich Drexler	38
Contraindications for RSWT	Ulrich Drexler	42
Mechanical influence on the muscle-tendon complex	Konstantin Karanikas	45

### Specific section

Radial shock wave therapy: Optimization of treatment success when using new technologies/materials	Conny Ulrich	64
Insertion tendinopathies of the shoulder	Ulrich Drexler	74
Lateral and medial epicondylitis of the humerus	Ulrich Drexler	90
Other insertion tendinopathies in the region of the upper extremities	Ulrich Drexler	102
Mid-portion and tendo-osseous tendinopathy of the Achilles tendon	Ulrich Drexler	104
Plantar fasciitis – calcaneal spur	Ulrich Drexler	114
Patellar tendinopathy, jumper's or runner's knee	Ulrich Drexler	120
Tendinopathies of the ischiocrural musculature	Ulrich Drexler	127
Insertion tendinopathy of the hip adductors	Ulrich Drexler	134
Greater trochanteric pain. Chronic trochanter major syndrome	Ulrich Drexler	138
Iliotibial band friction syndrome (runner's knee), insertion tendinopathy of the lateral tibial head and Gendy's tubercle	Ulrich Drexler	144
Rare tendinopathies of the lower leg / foot	Ulrich Drexler	148
Supplemental exercises for shock wave therapy	Markus Faber	152
Concluding and summarising remarks	Ulrich Drexler	174

### List of abbreviations

178

### Background literature

180

# INTRODUCTION

/ Ulrich Dreisilker

The great response from medical colleagues and physical therapists to the first publication on the subject of ESWT for enthesiopathies / tendinopathies ("Enthesiopathies," Leveho Verlag, October 2010) was the motivation for this second volume. This book is intended to be helpful and stimulating for all physicians, physical therapists and sports scientists interested in shock wave therapy for tendinopathies.

Extracorporeal shock wave therapy (ESWT) is constantly being developed further: numerous scientific studies have shown how successful radial shock wave therapy (RSWT) is for tendinopathies and that it achieves even better results when accompanied by stretching / load-bearing exercises.<sup>22-25</sup> Shock wave cross-friction for tendinopathies enables low energy dosing, which is sufficient to stimulate tendon fibre proliferation and collagen synthesis. Doppler sonography (PDI) for imaging pathological capillaries (neovascularisation) is another milestone in the diagnosis and therapy monitoring of tendinopathies.

It is well known that muscle and tendon form a functional element together. Understanding tendon pathologies requires knowledge of muscle pathophysiology, on which M. Gleitz has reported extensively! This volume makes multiple references to Gleitz' work as well as to the contribution from K. Karanikas ("Mechanical influence on the muscle-tendon complex," p. 45).

Tendon insertion disorders are not only a problem of older patients and degenerative changes from overexertions in daily life. They also occur as the result of improper training plans and the over- or under-training of athletes. While treatment and sports medical advice have fortunately improved for high-performance and elite sports in recent years, there is a great need to catch up in the care of recreational athletes and amateurs.

Further development of ESWT

Tendon insertion disorders are widespread.

The myofibrils themselves are formed from the contractile filaments actin (thin) and myosin (thick) (fig. 4). The thick filaments contain the myosin, which consists of a long shaft with two ball-like heads on the end.

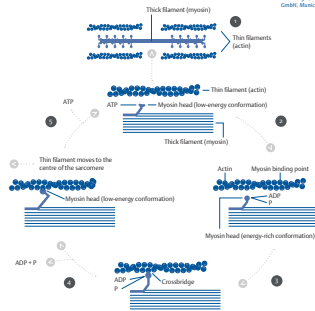
Additional proteins, such as troponin and tropomyosin, are deposited in the furrows between the two actin strands and function as control proteins. In the non-contracted state of the muscle fibre, the heads of the myosin filaments stand perpendicular to the actin filaments.

These heads bind to the actin filaments upon nerve signals, split the fuel ATP and draw the actin filaments together. In this phase, chemical energy is converted into mechanical energy. After this action, the heads of the myosin detach from the actin filaments again and swing back to their initial position. ATP is consumed in this process.

Externally visible muscle shortening occurs. This mechanism is known as the cross-bridge cycle and is implemented by the neural excitation of muscle fibres with the help of the transmitter *acetylcholine*.

HYPOTHESIS ON FORCE GENERATION DURING MUSCLE CONTRACTION | Fig. 4

Complatt, Wolf A. & Korte, Jano  
©. Biologie, Pearson Deutschland  
GmbH, Munich 2009, p. 148E.



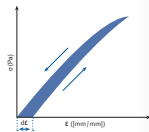
- 1> The myosin head with bound ATP is in the low-energy conformation.
- 2> The myosin head hydrolyses ATP to ADP and inorganic phosphate (P) and is then in an energy-rich conformation.
- 3> The myosin head binds to actin and forms a cross-bridge.
- 4> Through the release of ADP and P, the myosin head tips into the low-energy conformation and draws the thin filament in the direction of the centre of the sarcomere.
- 5> The binding of another ATP molecule leads to the release of the myosin head. This can then assume the energy-rich conformation again, and a new cycle can begin.

### THE SERIAL (SE) AND PARALLEL ELASTIC ELEMENTS (PE) – CONNECTIVE TISSUE

Serial (SE) and parallel elastic elements (PE) have many common structural properties. The distinguishing features essentially concern the elasticity, plasticity, viscosity and especially the stiffness of the individual structures. The tendons, for example, exhibit great stiffness and good elasticity. Tendons are able to convert stored energy into kinetic energy during an elongation. Fasciae have less stiffness and greater plasticity, so that a greater hysteresis loop remains after an elongation. This is comparable to the structure of a plastic bag, which does not return to its original form after being stretched and keeps the deformation (fig. 5).

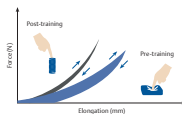
Modified from Brackmann  
et al. 2012 p. 38 Orthopaedie  
Bismarcker MV-Verlag

TENSION-ELONGATION DIAGRAM OF CONNECTIVE TISSUE | Fig. 5.0



The tension-elongation diagram of the connective tissue follows a hysteresis loop (according to J.A. Ewing, variant delayed behaviour on the input size).

TRAINED AND UNTRAINED CONNECTIVE TISSUE | Fig. 5.1



Modified from Brackmann  
et al. 2012 p. 38 Orthopaedie  
Bismarcker MV-Verlag

Trained connective tissue with good elasticity (tendon) has a smaller hysteresis loop (like a spring). Connective tissue with plastic properties has a larger hysteresis loop (like a sponge). Patients with a weakness in their connective tissue have a large hysteresis.

The different properties of the tendon (serial element) and the fasciae (parallel elastic element) are explained in the following.

### TENDON

The tendon is part of the connective-tissue, non-contractile elements of the muscle. It is integrated in the continuum of the connective-tissue structures of the muscle, which begins on the bone in the tendo-osseous transition and continues to the tendon. Connective tissues of the tendon, in the form of the epimysium, perimysium and endomysium, transition into the connective tissue of the muscle body.